

## Drug induced Tubulo-Interstitial Nephritis at King Khalid National Guard Hospital, Jeddah.

SAAD AL SHOHAIB, MD, FRCP(C)

*Department of Medicine, King Khalid National Guard Hospital, Jeddah, Saudi Arabia*

**ABSTRACT.** Acute tubulo-interstitial nephritis (TIN) is a well known complication of many drugs such as antibiotics, diuretics, non-steroidal anti-inflammatory drugs, therapeutic agents, and chemicals such lithium and platinum. It is characterized by a triad of rash, fever and eosinophilia. We present here the clinical features and management outcome of 8 cases encountered in our hospital over the last 5 years. Antibiotics were the inducing agent in 6 of the 8 cases, while the remaining two cases were induced by frusemide and lithium. The most common inducing antibiotic in our area was amoxycillin (4/8 cases). A case of drug-induced TIN by cefotaxime was encountered in the study, which we believe to the best of our knowledge is the first report of drug-induced TIN by this antibiotic. All the patients made excellent recovery by the withdrawal of the inducing drug, steroid therapy and dialysis in some cases. A high index of suspicion is required to make an early diagnosis and to prevent renal damage. Clinical diagnosis can be confirmed by renal biopsy.

**Keywords:** Drug induced tubulo-interstitial nephritis, Diagnosis, Treatment.

### Introduction

Acute tubulo-interstitial nephritis (TIN) is most often due to a hypersensitivity reaction to various drugs, most commonly due to antibiotics (beta-lactam agents such as penicillins, and cephalosporins, rifampicin sulphonamides); non-steroidal anti-inflammatory drugs (NSAIDs); diuretics (frusemide, thiazides) and other drugs such as phenindione allopurinol, cimetidine, phenytoin, lithium and platinum<sup>[1,2]</sup>. The cardinal

---

Correspondence & reprint requests: Dr. Saad Al Shohaib, Department of Medicine, King Khalid National Guard Hospital, P.O. Box 9515, Jeddah 21423, Saudi Arabia.

Accepted for Publication: 28 December 2001 Received: 21 October 1999

pathological changes in TIN consist of inflammatory cell infiltration of the interstitium, with moderate tubular damage, but normal glomeruli. The interstitial infiltrates generally consist of acute inflammatory cells. Often eosinophilic, but sometimes plasma cells predominate and oedema may be marked<sup>[2]</sup>. Although drugs are increasingly considered as an important cause of acute renal failure (ARF), the incidence of drug-induced TIN is uncertain because of incomplete notification, insecure diagnosis and more importantly the population exposed to individual drugs is difficult to quantify<sup>[3,4]</sup>.

The clinical features of acute drug-induced TIN classically begin abruptly with fever (85-100% of patients), arthralgia, maculopapular rash (25-50% of patients), macroscopic or microscopic haematuria (95% of patients) and acute oliguric or non-oliguric renal failure<sup>[1,2]</sup>. Sterile pyuria, mild proteinuria (less 2 g/ 24 hr) and eosinophilia are frequently found<sup>[2]</sup>. Eosinophilia, typically lasting only one or two days, occurs in 80% of the patients.

The purpose of this study was to review the cases of acute TIN seen in our hospital over the last 5 years and to call the attention of physicians to the occurrence of this condition and its unusual presentation in some instances.

### **Materials and Methods**

A retrospective study of the records of all patients admitted to the Renal Unit of King Khalid National Guard Hospital, Jeddah, was carried out covering the last 5 years. During this period, 1,149 patients were registered at our Nephrology clinic, having been referred from various hospitals mainly in the Jeddah area and the western region of the Kingdom. Of these patients, 276 were diagnosed as ARF and 200 kidney biopsies were carried out. Eight were histologically confirmed as TIN. Patients with ARF and TIN were segregated in separate computer files for later analysis. Computer files were obtained from the Management Information System (MIS) of the hospital. The following information was obtained from the files via: age, sex, dates of admission and discharge, history on admission, clinical features, investigations and diagnoses. Also obtained were the drugs received before and during hospitalization, and details of treatment. The possibility of environmental or occupational toxic exposure was ascertained from the patient or the relatives.

### **Results**

During the study period, 8 patients were identified with ARF, who developed TIN. In all the patients, the diagnosis was made on clinical grounds and confirmed by renal biopsy. The TIN inducing drugs were amoxicillin in 4 patients, and 1 case was induced by frusemide, cefotaxime, rifampicin, and lithium. The clinical features, investigations and management of these patients are shown (see Table 1). The interval between taking the TIN-inducing drug and the appearance of symptoms ranged from 7 to 14 days. Five patients presented with fever while 3 were afebrile. One patient presented with skin rash and eosinophilia, while the others presented with fatigue and

weakness. Five patients were oliguric on admission while the remaining 3 were non-oliguric. Four patients required haemodialysis, 3 of whom required dialysis for less than 2 weeks while the remaining 1 required dialysis for 6 weeks. Treatment of the patients was affected by withdrawing the inducing drug and therapy with prednisolone 1 mg/kg/per day and gradually reduced over a period of 4 to 6 weeks. All the patients made a successful recovery and their serum creatinine returned to normal within 6 months of starting treatment.

TABLE 1. Clinical Features of Patients with Drug-Induced Tubulo-Interstitial Nephritis.

Case No.	Sex	Age	Fever	Skin Rash	Eosinophilia	24hr Urine Protein	Maximum Serum Creatinine (Umol/L)	Dialysis Required	Renal Signs	Inducing Drug
1	M	28	+	-	-	850	1200	Yes	Oliguric	Cefotaxime
2	M	23	+	-	-	950	1200	Yes	Oliguric	Amoxycillin
3	F	55	+	+	+	750	1200	Yes	Oliguric	Amoxycillin
4	F	55	-	-	-	1000	800	No	Oliguric	Frusemide
5	M	40	+	-	-	650	500	No	Non-Oliguric	Rifampin
6	F	30	-	-	-	750	400	No	Non-Oliguric	Amoxycillin
7	M	48	+	-	-	700	900	Yes	Oliguric	Amoxycillin
8	M	48	-	-	-	750	700	No	Non-Oliguric	Lithium

## Discussion

Acute TIN is a well known complication of many drugs including antibiotics, diuretics, analgesics, and chemicals such as platinum<sup>[5]</sup> and lithium<sup>[6]</sup>. The pathogenesis of drug-induced TIN in humans is largely unknown and is at present purely putative<sup>[2]</sup>. Present knowledge is based on animal models of immunological disturbances which can produce TIN and these fall into three categories. Firstly, immune complex (immunoglobulin and complement) deposition in the interstitium or on tubular basement membrane<sup>[7]</sup>. The relevance of this pathogenic mechanism to human drug-induced TIN is not quite clear. Secondly, anti-tubular basement membrane (anti-TBM) antibody formation has been proposed in methicillin nephritis<sup>[8]</sup>, but anti-TBM antibodies have rarely been demonstrated in other drug-induced TIN<sup>[7]</sup>. Thirdly, although there is no firm evidence that cell-mediated mechanisms are important in the production of human TIN, they have been implicated in animal models<sup>[9,10]</sup>. Based on histological evidence, it has been suggested that cell membrane mechanisms of injury are likely to be paramount in clinical TIN<sup>[11]</sup>.

The diagnosis of drug-induced TIN requires a high index of suspicion, and can easily be missed, especially in patients who make a spontaneous recovery. In any patient with renal failure of obscure aetiology, a detailed history of drug intake (both prescribed and self-administered) should be obtained from the patient or close relatives, as well as, any

possible environmental or occupational toxic exposure. There are at least two main types of presentations of TIN. The first is typified by methicillin nephritis, which occurs several days after regular intake of the drug has been commenced and has a rather indolent presentation<sup>[2]</sup>. The second is a relatively more sudden presentation with fever, rigors, arthralgia, nausea, vomiting, diarrhoea, and oliguria occurring within hours of re-exposure to the inducing drug. This type of presentation follows re-exposure to a drug such as rifampicin, well-tolerated during an earlier course of treatment, but precipitating an acute multi-system disturbance on a second encounter. In all instances, apart from detailed history and routine investigations of renal function, the diagnosis is best confirmed by renal biopsy. It should be remembered that the classical triad of rash, fever, and eosinophilia commonly used to suspect TIN occurs in less than 30% of the patients. The diagnosis should be suspected in any case of ARF of obscure or unknown aetiology.

Patients in intensive care units or those with severe liver diseases, are exposed to several medications including antibiotics and analgesics. They are liable to development of TIN with insults to the kidney if the possibility of TIN is not born in mind. For example, 1 of our patients (see Patient No. 4 in Table 1), was known to have liver cirrhosis. She developed severe oedema and frusemide was given with albumin infusion. She initially had diuresis, but 7 days later, she became oliguric and her creatinine rose from 220  $\mu\text{mol/L}$  to 800  $\mu\text{mol/L}$ . It was presumed that she has hepatorenal syndrome, but she looked clinically to well for this syndrome. However, a renal biopsy confirmed the presence of acute interstitial nephritis. The discontinuation of frusemide and therapy with butamide 2 mg 12 hourly for 2 weeks led to her improvement and return of the renal function to normal. The creatinine decreased to 240  $\mu\text{mol/L}$  and stabilised at that level.

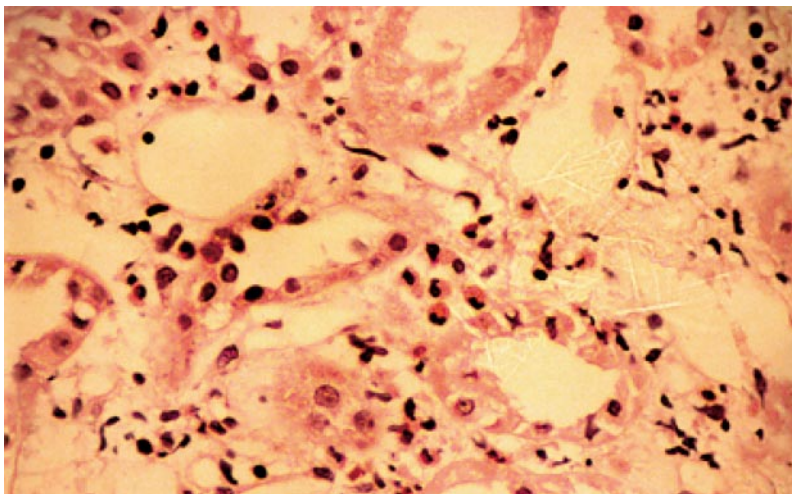


FIG.1. Photomicrograph of the renal biopsy of one of the patients showing the characteristic histological features of TIN.

The most common cause of drug-induced TIN in this series was amoxicillin. This is not surprising since it is a widely prescribed antibiotic in our area and it can be readily obtained over the counter in most pharmacies. Hence, the extent of antibiotic-induced TIN in our locality, as with many developing countries, will be difficult to estimate. The cephalosporins had been associated with TIN, *i.e.*, cephalothin<sup>[12,13]</sup>, cephalixin<sup>[14]</sup>, cephradine<sup>[15]</sup>, and cefoxitin<sup>[16]</sup>. This is not surprising since the drugs are structurally related with the same nucleus. One of our patients developed drug-induced TIN following ingestion of cefotaxime, another cephalosporin, similar to the cephalosporins reported above. To our knowledge, this is the first report of cefotaxime-induced TIN.

In addition to withdrawal of the suspected drug and the usual management of renal failure, steroids often in high doses are frequently recommended for the treatment of acute drug-induced TIN<sup>[1,2]</sup>. Some patients may require dialysis for management of the acute renal failure as in the present series. Overall, most patients make a good recovery of their renal function as all our patients did. However, the importance of a high index of suspicion cannot be overemphasised if correct diagnosis is to be achieved early and severe renal damage prevented.

#### References

- [1] **Kumar P, Clark M.** Renal Disease. In: Kumar, and Clark, M. eds. *Clinical medicine: a textbook for Medical Students and Doctors*. 3<sup>rd</sup> edition. Baillere Tindall. London. 1994: 461.
- [2] **Newstead CG, Marsh FP.** In: Catto GRD. ed. *New Clinical Applications: Nephrology, drugs, and the kidney*. Kluwer Academic Publishers. Dordrecht. 1990: 37-63.
- [3] **Linton AL, Clark WF, Driedger AA, Turnbull DR, Linday RM.** Acute interstitial nephritis due to drugs: review of the literature with a report of nine cases. *Ann Intern Med* 1980; **93**(5): 735-741.
- [4] **Kleinknecht D, Vanhille P, Morel-Maroger L, Kanfer A, Lemaitre V, Mery JP, Laederich J, Cal-lard P.** Acute interstitial nephritis due to drug hypersensitivity. An up-to-date review with a report of 19 cases. *Adv Nephrol Necker Hosp* 1983; **12**: 277-308.
- [5] **Dentino M, Luft RC, Yum NM, Williams SD, Einhorn LH.** Long-term effect of cis-diamminedichloride platinum (CDDP) on renal function and structure in man. *Cancer* 1978; **41**(4): 1274-1281.
- [6] **Hestbech J, Hansen HE, Amdisen A, Olsen S.** Chronic renal lesions following long-term treatment with lithium. *Kidney Int* 1977; **12**(3): 205-213.
- [7] **McCluskey RT, Colvin RB.** Immunologic aspects of renal tubular and interstitial diseases. *Ann Rev Med* 1978; **29**: 191-203.
- [8] **Border WA, Lehman DH, Egan JD, Sass HJ, Glode JE, Wilson CB.** Antitubular basement membrane antibodies in methicillin-associated interstitial nephritis. *N Engl J Med* 1974; **291**(8): 381-384.
- [9] **Van Zwieten MJ, Leber PD, Bhan AK, and McCluskey RT.** Experimental cell mediated interstitial nephritis induced with exogenous antigens. *J Immunol* 1977; **118**(2): 589-593.
- [10] **Baldamas CA, Kachel G, Koch C, Schoeppe W.** Cellular immune mechanisms in experimental tubulo-interstitial nephritis (TIN). *Contrib Nephrol* 1979; **16**: 141-146.
- [11] **Cameron JS.** Allergic interstitial nephritis: clinical features and pathogenesis. *Q J Med* 1988; **66**: (250): 97-115.

- [12] **Durham DS, Ibels LS.** Cephalothin induced acute allergic interstitial nephritis. *Aust N Z J Med* 1981; **11(3)**: 266-267.
- [13] **Milman M.** Acute interstitial nephritis during treatment with penicillin and cephalothin. *Acta Med Scand* 1978; **203(3)**: 227-230.
- [14] **Verma S, Kieff E.** Cephalixin related nephropathy. *JAMA* 1975; **234(6)**: 618-619.
- [15] **Wiles CM, Assem SE, Cohen SL, Fisher C.** Cephradine induced interstitial nephritis. *Clin Exp Immunol* 1979; **36(2)**: 342-346.
- [16] **Haskell RJ, Fujita NK, Stevenson JA, Border WA.** Cefoxitin induced interstitial nephritis. *Arch Intern Med* 1981; **141(11)**: 1557.

## الأدوية المحفزة لالتهابات أنسجة قنوات الكلى بمستشفى الملك خالد للحرس الوطني

سعد الشهيب

استشاري أمراض الكلى

قسم الأمراض ، مستشفى الملك خالد للحرس الوطني

جدة - المملكة العربية السعودية

المستخلص. تحدث التهابات ما بين الأنسجة الكلوية كمضاعفات لكثير من العقاقير مثل المضادات الحيوية ومدرات البول ومضادات الالتهابات غير الستيرويدية بالإضافة لبعض المواد الكيماوية مثل الليثيوم والبلائين. وفي هذا البحث نصف ثمان (8) حالات مرضية من الناحية التشخيصية والعلاجية وكل هذه الحالات تم تشخيصها بمستشفى الملك خالد بجدة على مدى خمس سنوات .

لقد كان السبب الرئيسي هو المضادات الحيوية (في ست من هذه الحالات ) بينما تسبب عقار الليثيوم والفروزاميد في الحالتين الأخريين .

وقد سجلنا حالة واحدة نتيجة السيفوتاكسيم وهي الحالة الأولى التي تم تسجيلها . لقد تم شفاء جميع المرضى بعد إيقاف العقار المسبب بالإضافة إلى عقار البردينزولون وبعض الحالات احتاجت إلى غسيل الكلى (الديليزة) .

ونشير في هذا البحث إلى ضرورة توقع هذه الحالات وترقبها وتشخيصها المبكر لمنع الضرر على الكلى .

ولا بد من الإشارة أن التشخيص يتم التأكد منه عن طريق الخزعة الكلوية .